Successful repair of subacute traumatic bronchopleural fistula using endobronchial valve

J. Lee[1], S. Bhagvan[2], I. Civil[3], C. Lewis[4], A. Sibal[5]

Auckland City Hospital, New Zealand

Introduction

- Tracheobronchial injury (TBI) is a potentially a life-threatening condition with most common causes being either physical trauma or iatrogenic - mortality ranging between 25 to 50%.
- Despite this, TBIs due to blunt trauma are relatively rare, only occurring in about 0.2–5% of all cervical and thoracic injuries.
- Insertion of a one-way endobronchial valve (EBV) as a conservative management option for TBIs has been suggested in multiple case series.
- We present details of a case, key points in selection of EBV as a therapeutic strategy, and description of the procedure.

Case

- A fit 26-year-old male presented with a right tension haemopneumothorax, severe pulmonary contusions and multiple fractures, following a high-speed motor vehicle crash.
- The patient, then, proceeded to video assisted thoracoscopic surgery and decortication on day 5, and 1,100 ml of blood was drained from right hemi-thorax.
- Development of a large new right hydropneumothorax and bronchopleural fistula (BPF) were seen on computed tomography (CT) scan on day 7.
- Proceeded to right thoracotomy, decortication, and repair of BPF on day 9, however, air leak persisted.
- Balloon occlusion technique via bronchoscopy identified air leaks in RB 8 and 9, therefore an EBV – (Spiration, size 9 mm) was inserted with the aim of removing it in 3 months.
- Symptoms resolved and the patient was discharged on day 25.

Discussion

- Prompt diagnosis of TBI using bronchoscopy is critical, despite the difficulties arising from the patients' critical condition.
- Guidelines recommend surgical repair as the gold standard after failure of conservative management – including tube thoracostomy drainage, chemical pleurodesis, and autologous blood patch pleurodesis.
- CT scan and bronchoscopy is the key in localizing BPFs and selecting the appropriate EBV devices.
- EBV can be an effective conservative treatment option for stable patients or high operative risk patients - may be the first line treatment in selected poly trauma patients with suspected BPFs.
- Metallic EBV (Spiration) was chosen because it provides rigid placement with low risk of migration and encourages granulation tissue formation. However, it has a higher risk of erosion/perforation long term, hence, the plan for removal in 3 months, once the BPF site is fully healed.
- Multiple independent case reports/series illustrate efficacy of using EBVs to manage persistent air leak – however there is a lack of prospective studies.

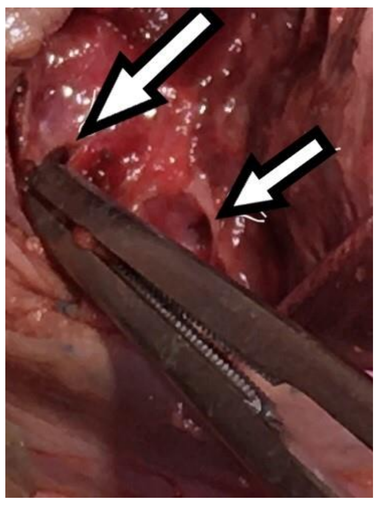

Fig 1.1 BPFs seen during thoracotomy

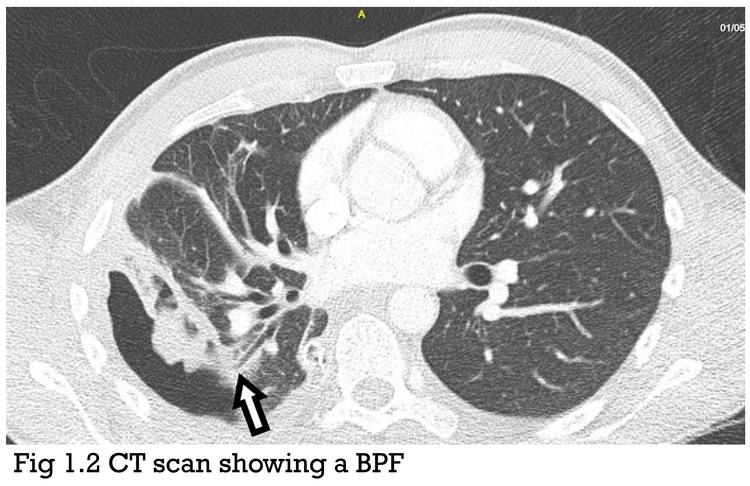

Fig 1.2 CT scan showing a BPF

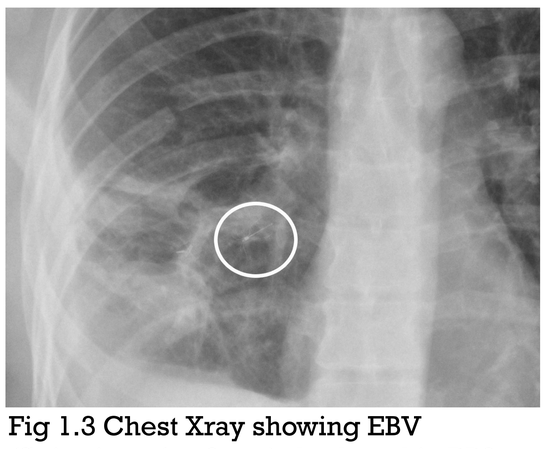

Fig 1.3 Chest Xray showing EBV (Spiration, size 9mm) deployed in RB9

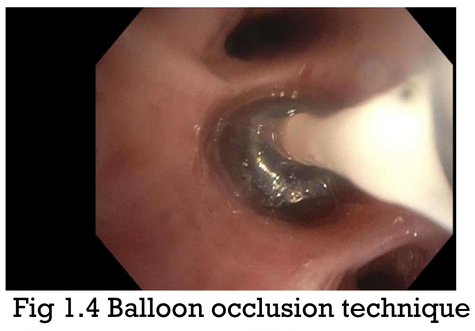

Fig 1.4 Balloon occlusion technique /Sizing of valve in RB9

Fig 1.5 Final site of EBV in RB9

Conclusion

EBV should be considered in the management of traumatic BPF in selected cases, as this could improve overall outcome post trauma and length of hospital stay.

References

- Dugan, K. C., Laxmanan, B., Murgu, S., & Hogarth, D. K. (2017). Management of persistent air leaks. *Chest*, *152*(2), 417-423.
- Grewal, H. S., Dangayach, N. S., Ahmad, U., Ghosh, S., Gildea, T., & Mehta, A. C. (2019). Treatment of tracheobronchial injuries: a contemporary review. *Chest*, *155*(3), 595-604.

Author information

1 - John Lee, House Officer, Cardiothoracic Unit, Auckland City Hospital
2 - Dr Savitha Bhagvan, General and Trauma Surgeon, Trauma Services, Auckland City Hospital
3 - Prof Ian Civil, Vascular and Trauma Surgeon, Trauma Services, Auckland City Hospital
4 – Dr Chris Lewis, Respiratory Physician, Respiratory Medicine Department, Auckland City Hospital
5 – Mr Amul Sibal, Cardiothoracic Surgeon, Cardiothoracic Unit, Auckland City Hospital

We thank Auckland City Hospital staffs who were involved in the care of this patient.